

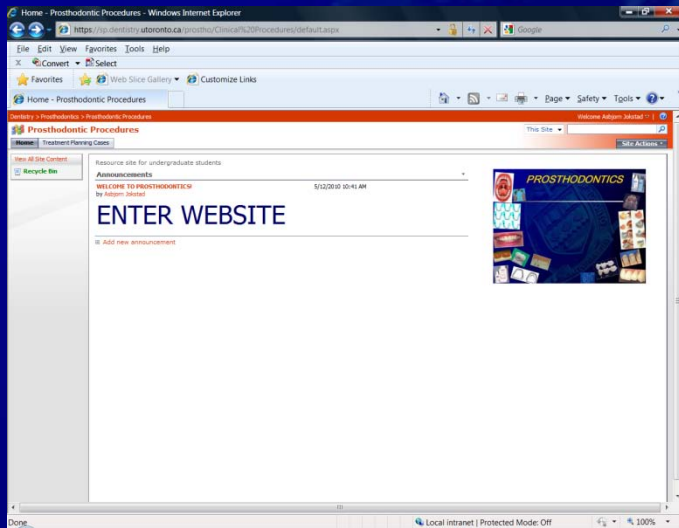
PROSTHODONTICS

3rd year - January 2011

Treatment planning

Asbjørn Jokstad
Head, Prosthodontics

Patient-based learning in small groups



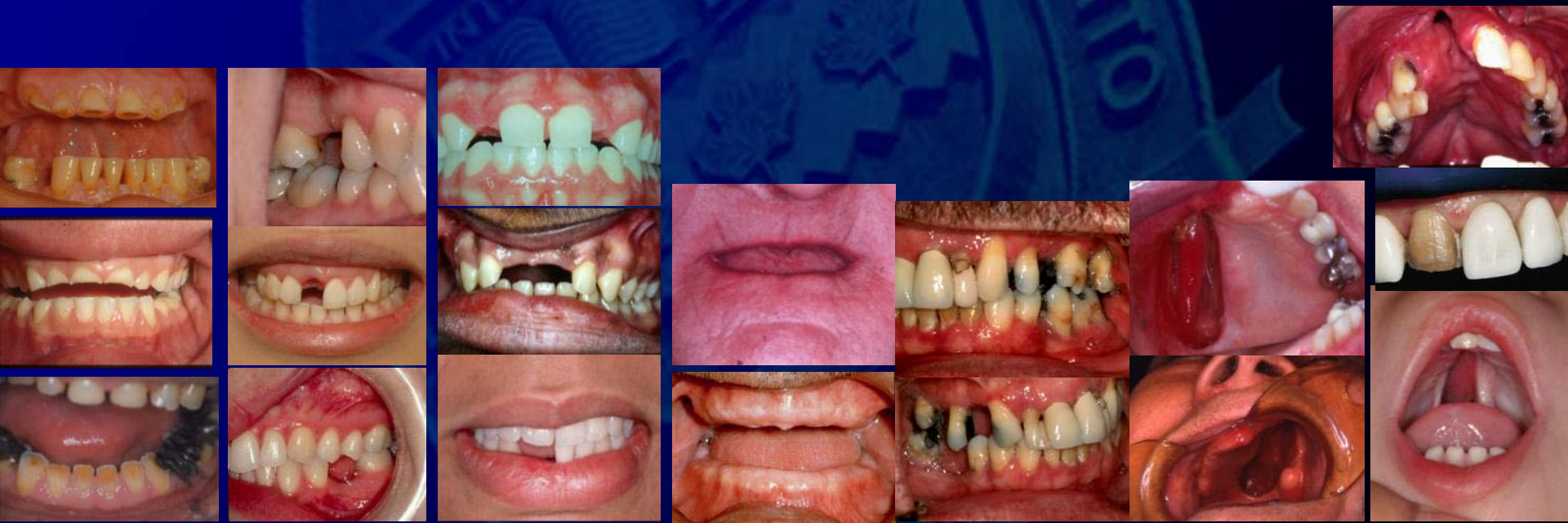*Dr Romeo Paculanan
Dr Joseph Fava
Dr Babak Shokati*

*Dr Aaron Fenton
Dr Reena Garcha
Dr Brett Ayliffe*

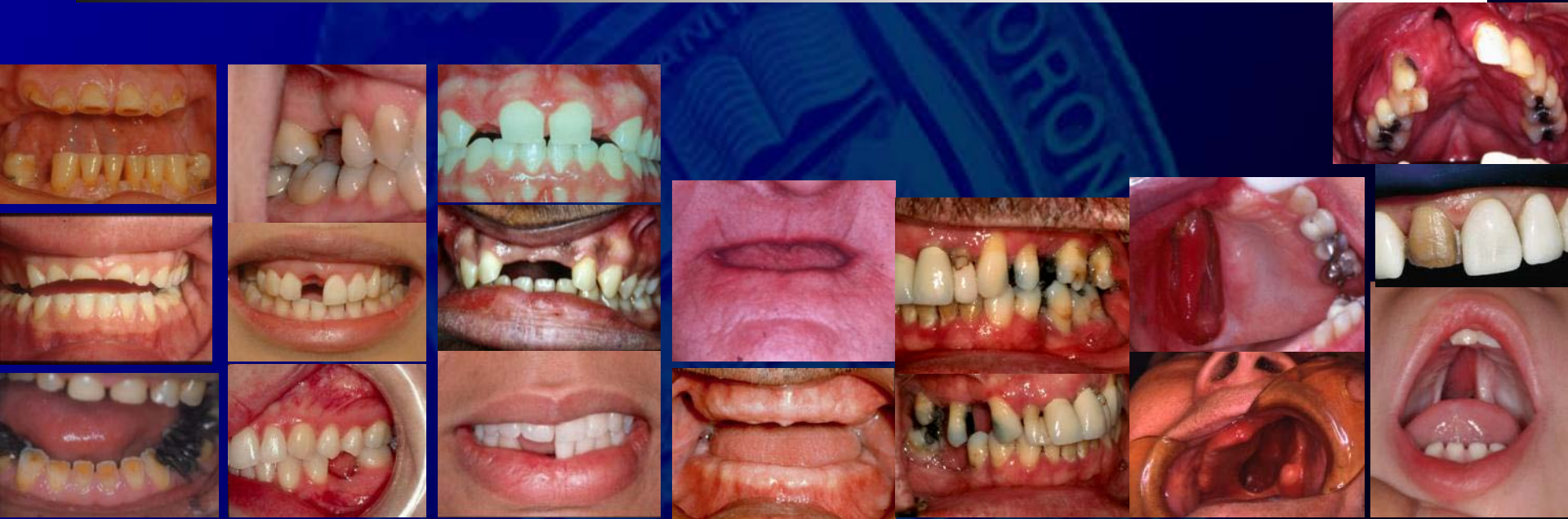Case 1	Case 2	Case 3	Case 4	Case 5	Case 6
Edentate, posterior maxilla	Single missing teeth posterior in all 4 quadrants	Edentate posterior (Single quadrant free-end) Maxilla (a)Mandible (b)	Edentate anterior & posterior (bounded)	Complete Edentulous Maxilla + Edentate posterior (Free end) Mandible	Complete Edentulous Maxilla & Mandible
January 4th January 6th	Small group sessions - Jan 4,6,7,11,13,20,25,27	January 11th January 13th	January 18th January 20th	January 25th January 27th	February 1st February 3rd
Supplement pictures	Supplement pictures	Supplement (a) Supplement (b) pictures	Supplement pictures	Supplement pictures	Supplement pictures
Technical solutions used for patients with comparable teeth:	Technical solutions used for patients with comparable teeth	Technical solutions used for patients with comparable teeth	Technical solutions used for patients with comparable teeth	Technical solutions used for patients with comparable teeth	Technical solutions used for patients with comparable teeth

The framework for the practice of prosthodontics

Competency to predictably treat patients with these conditions:



The common characteristics of these individuals' condition



Loss of:

Morphology

Function

Neuro-physiology mechanisms

What characterizes the individuals with these conditions?



How do each individual cope with their condition? →

Who becomes a patient?

Why?

What are their expectations for improvement?

Socio-cultural
determinants

A holistic approach to patient care

1. **SITUATION:** What is the patient's problem?

Wear

Single space

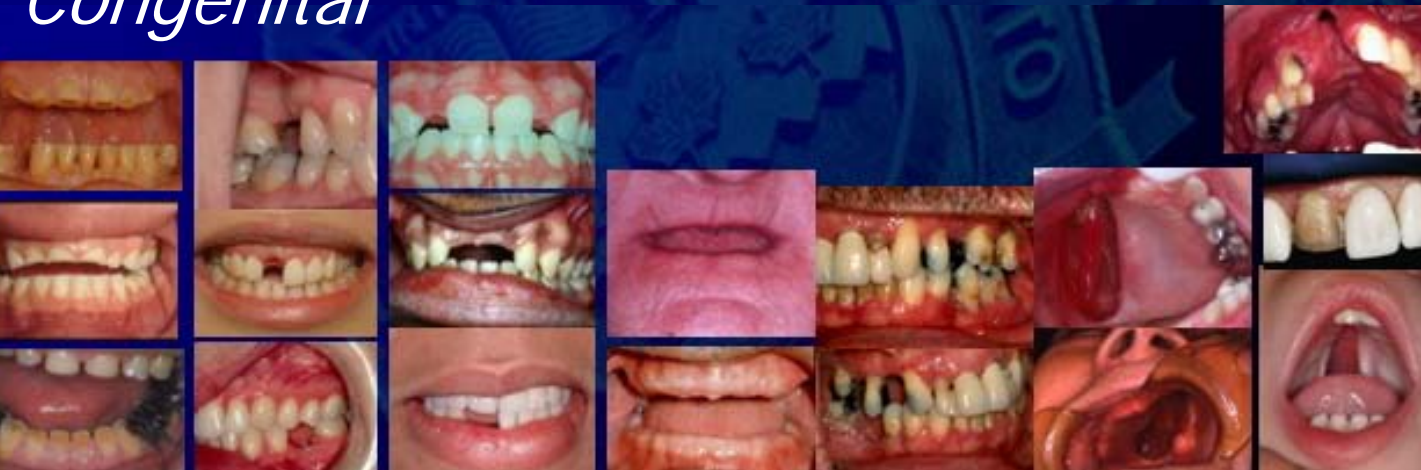Partial Dentate

Edentulous jaw

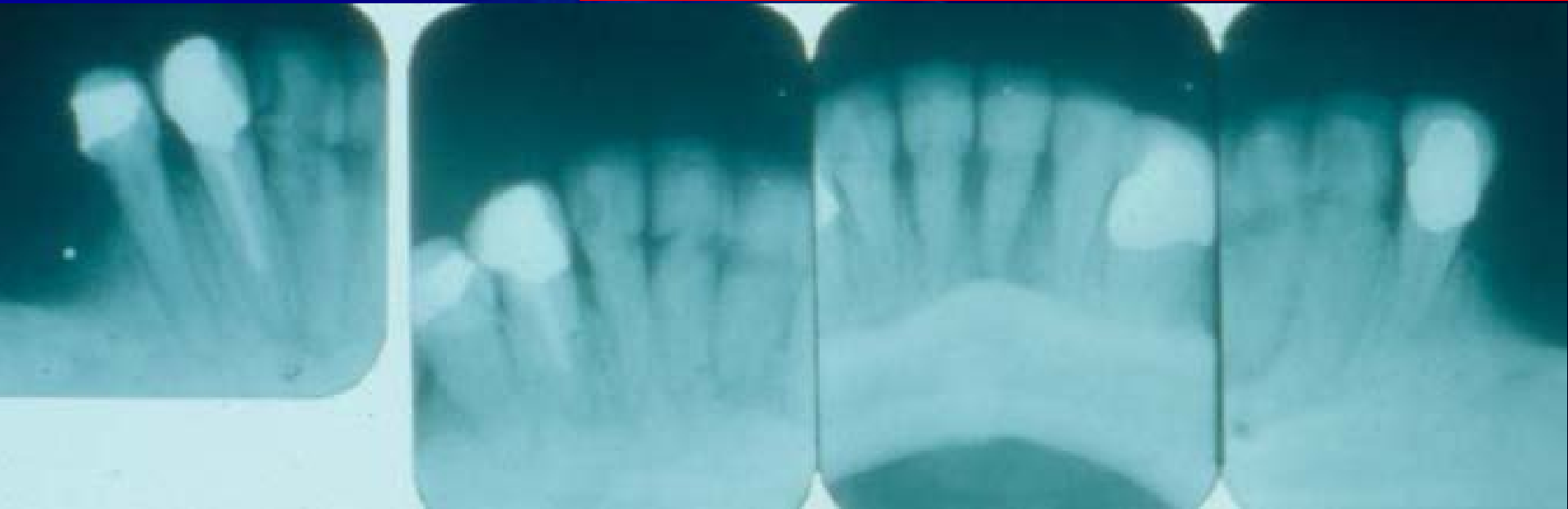Terminal dentition

Extensive tissue loss

Congenital



Choice of technical solution ?

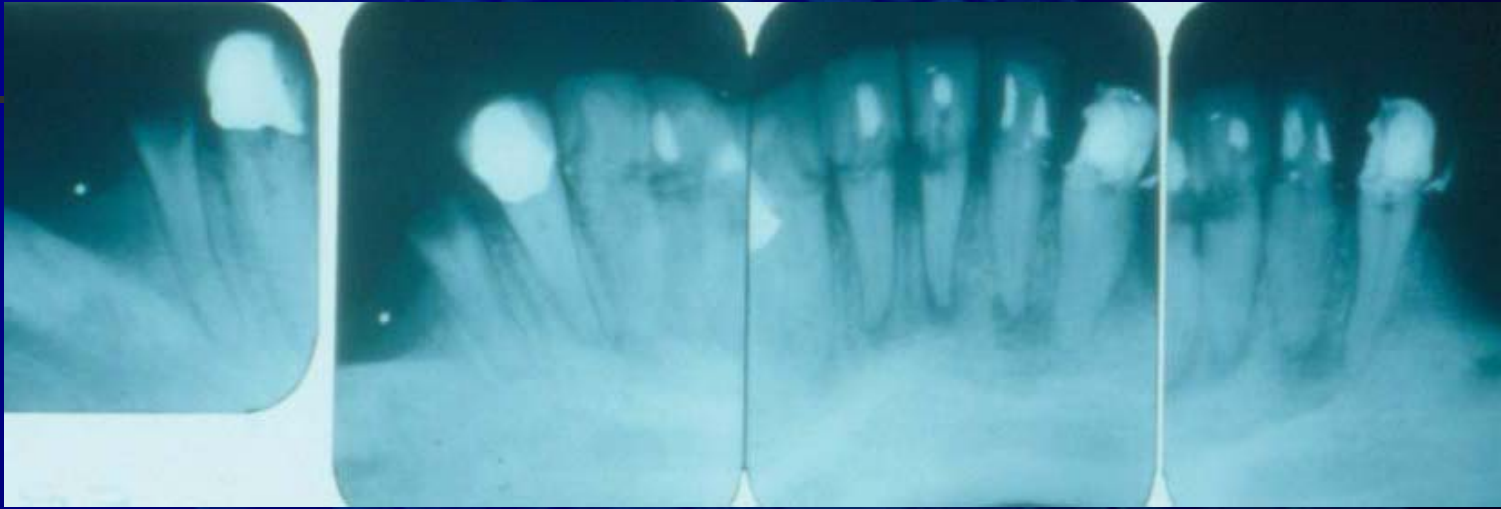
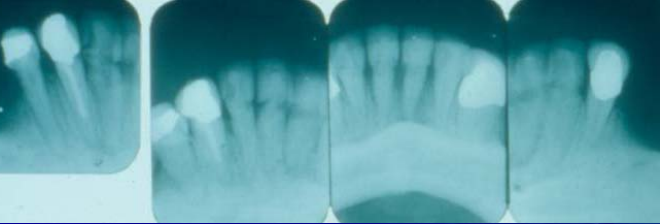

76 yrs
Dry mouth
Caries

?

- A. Restorative only, no prostho
- B. Cast partial denture +/- crowns
- C. Fixed bridge
- D. Implant retained prosthesis
- E. Other

Choice of technical solution ?

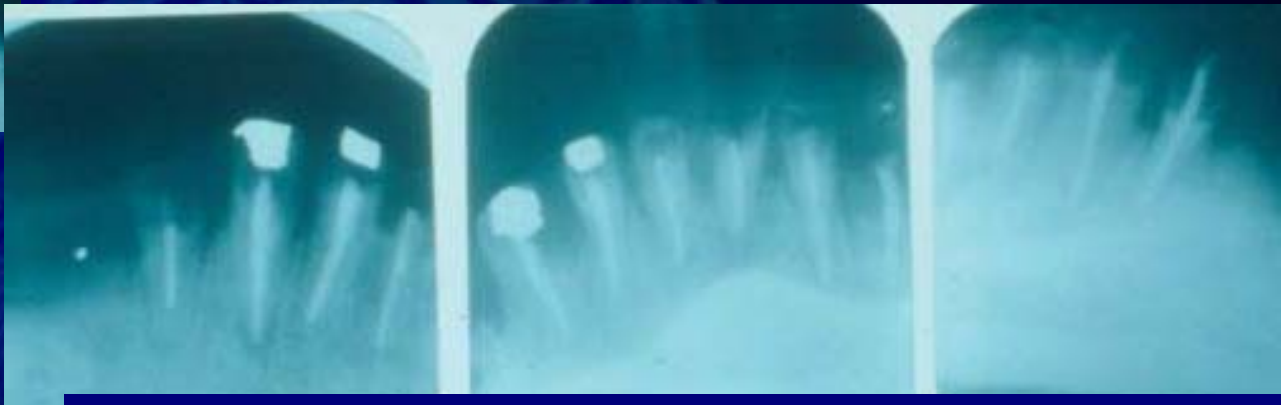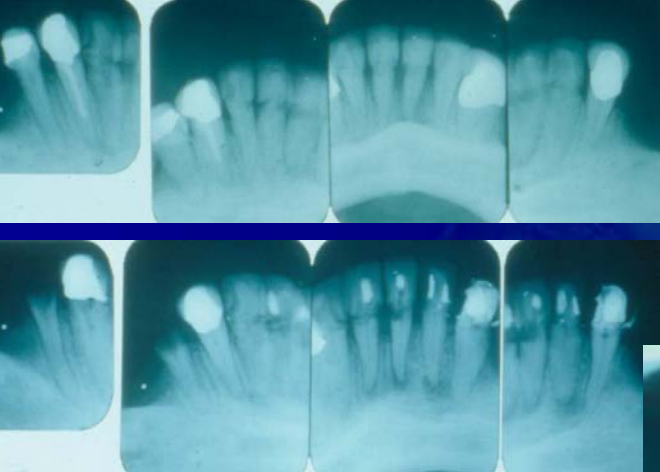


?

76 yrs + 2
Dry mouth
Caries

- A. Restorative only, no prostho
- B. Cast partial denture +/- crowns
- C. Fixed bridge
- D. Implant retained prosthesis
- E. Other

Choice of technical solution ?

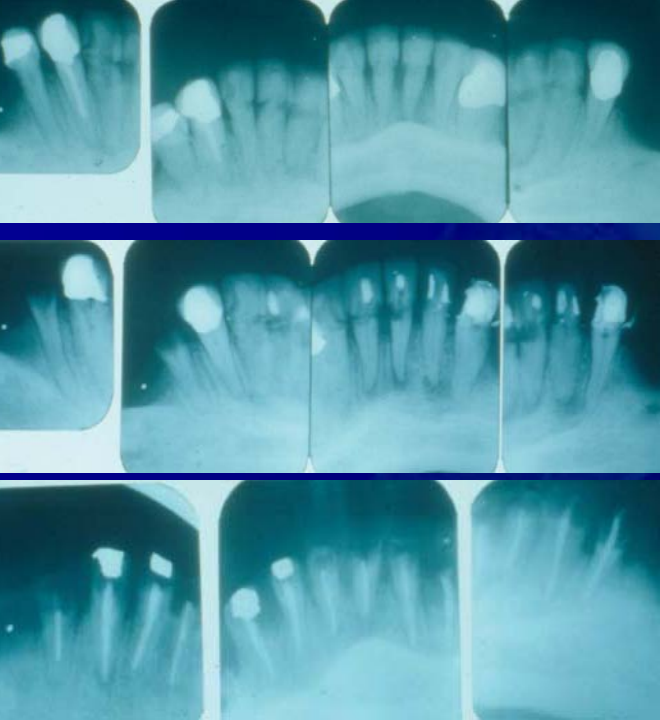


?

76 yrs + 2 + 1.5
Dry mouth
Caries

- A. Restorative only, no prostho
- B. Cast partial denture +/- crowns
- C. Fixed bridge
- D. Implant retained prosthesis
- E. Other

Choice of technical solution ?

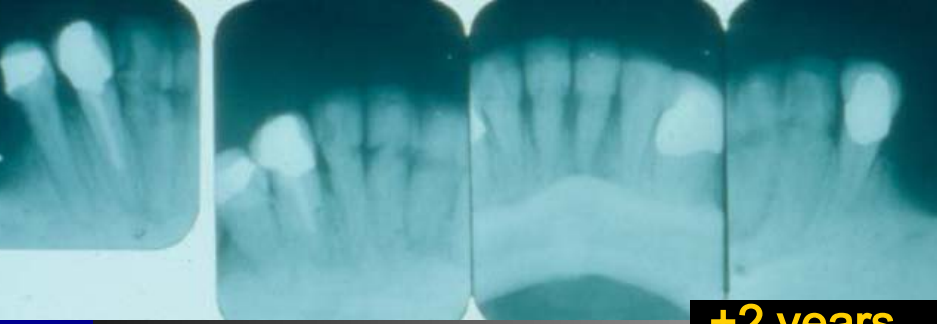

?

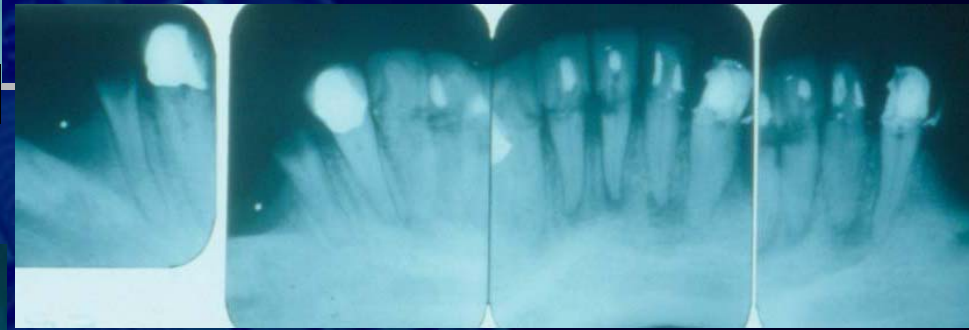
76 yrs + 2 + 1.5 + 1
Dry mouth
Caries

- A. Restorative only, no prostho
- B. Cast partial denture +/- crowns
- C. Fixed bridge
- D. Implant retained prosthesis
- E. Other

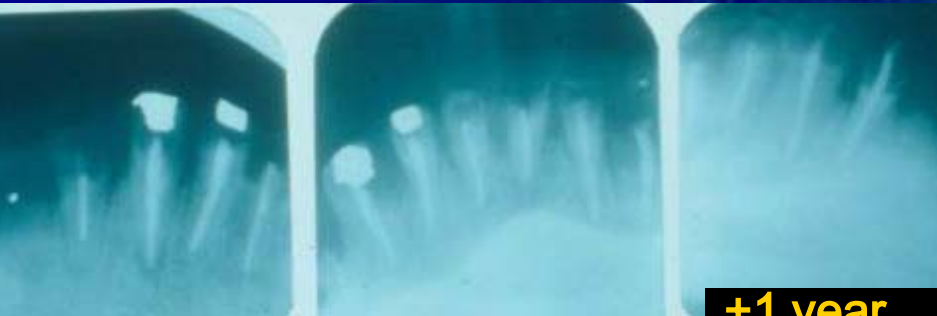**Choice of technical solution
≠ Patient management!**



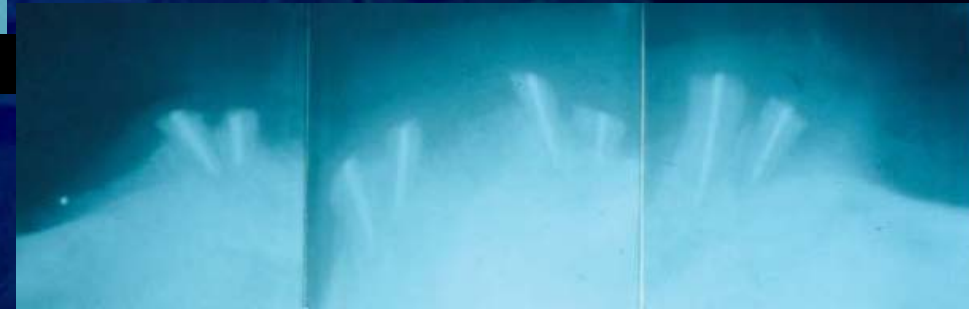+2 years



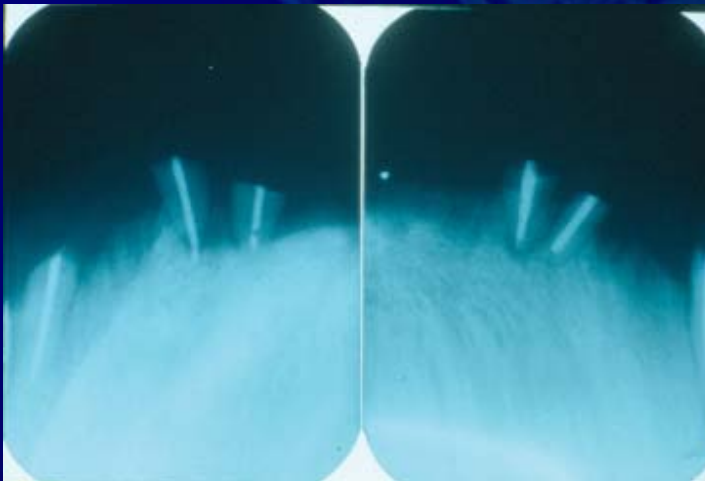+1.5 years



+1 year



+ <1 year



**Doing the right thing vs.
Doing the thing right**

A holistic approach to patient care

1. **SITUATION:** What is the patient's problem?
2. **CAUSE:** What is at the root of the patient's problem?
Active Disease?
Consequences of a disease?

Wear

Single space

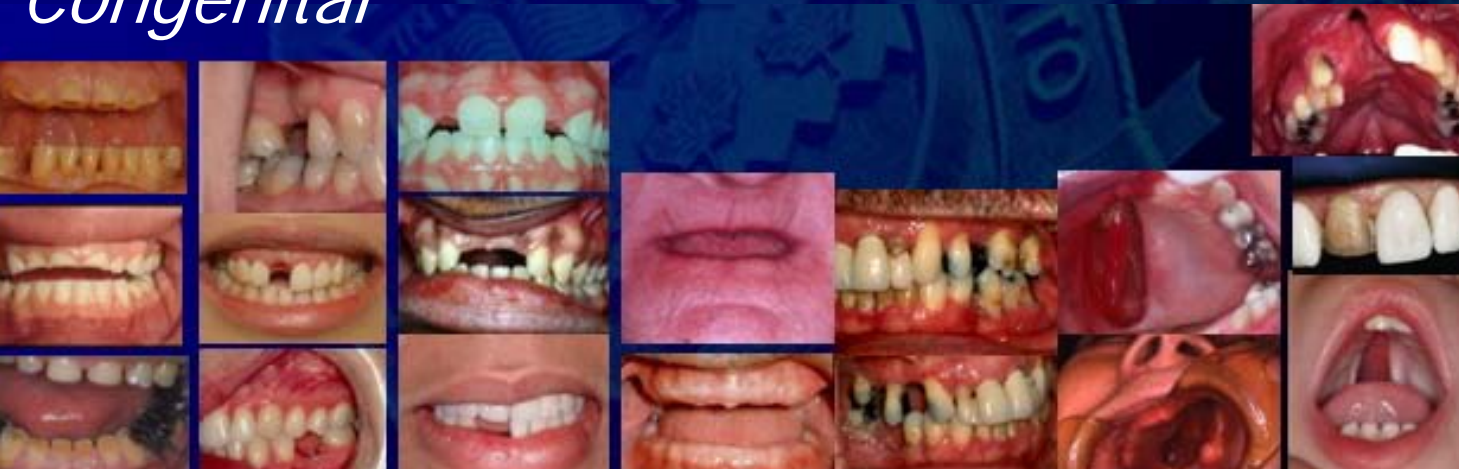Partial Dentate

Edentulous jaw

Terminal dentition

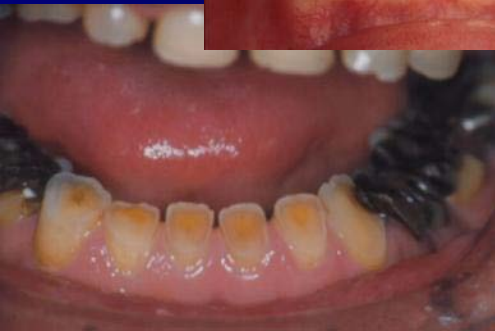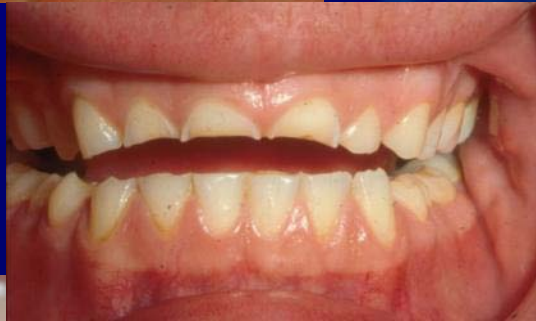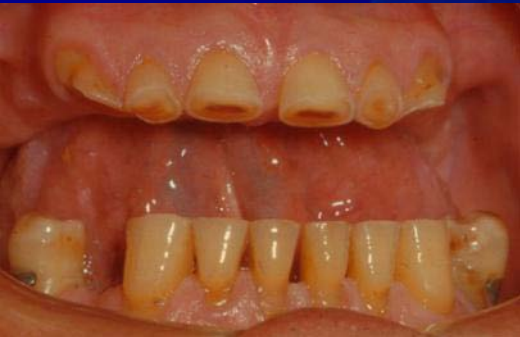Extensive tissue loss

Congenital



Considerations relative to the condition

Wear



Etiology?:

Friction

External (“abrasion”)

Internal (“attrition”)

Chemical (“corrosion/erosion”)

External (Diet)

Internal (e.g. GERD)

Considerations relative to the condition

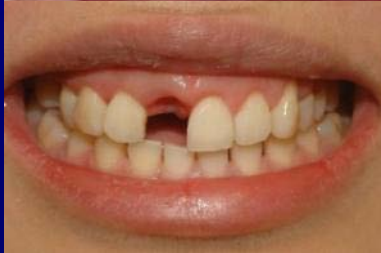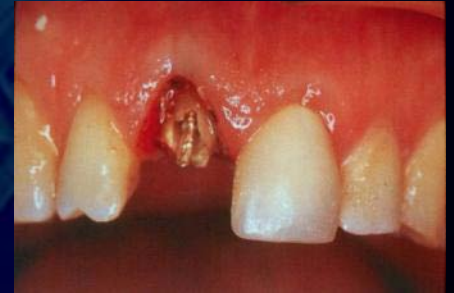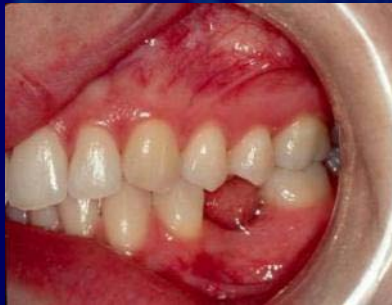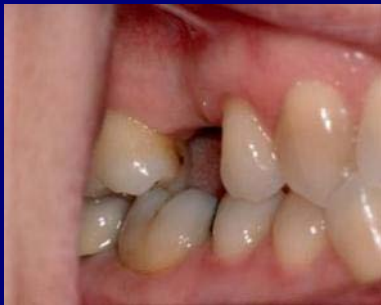Wear

Single space

Etiology?:

Trauma

Caries / Periodontitis



Considerations relative to the condition

Wear

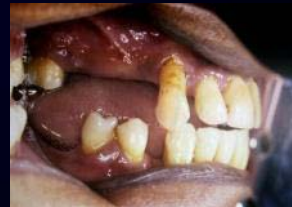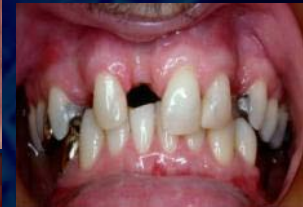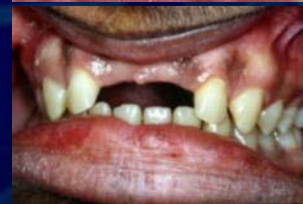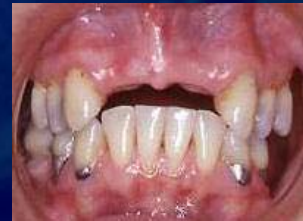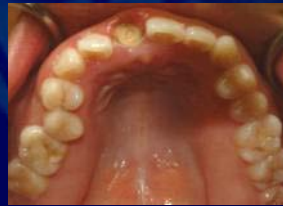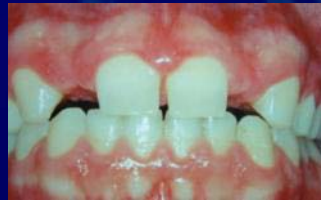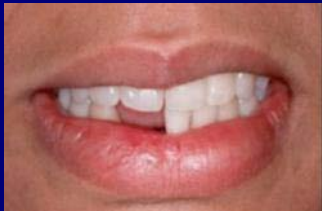Single space

Partial Dentate

Etiology?:

Trauma

Caries/ Periodontitis



Considerations relative to the condition

Wear

Single space

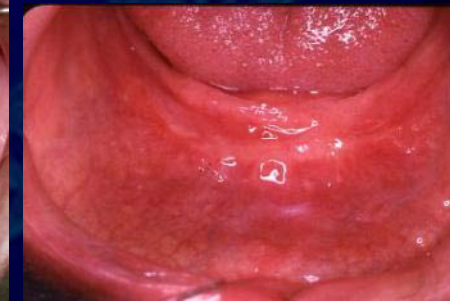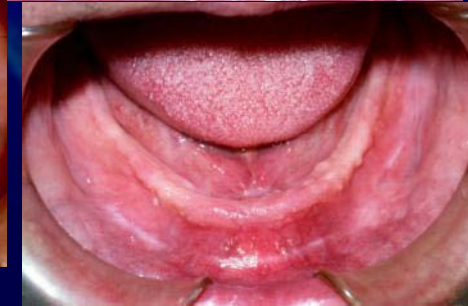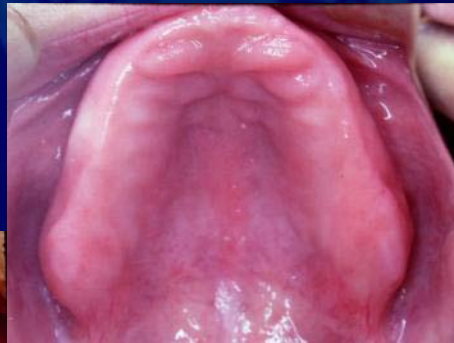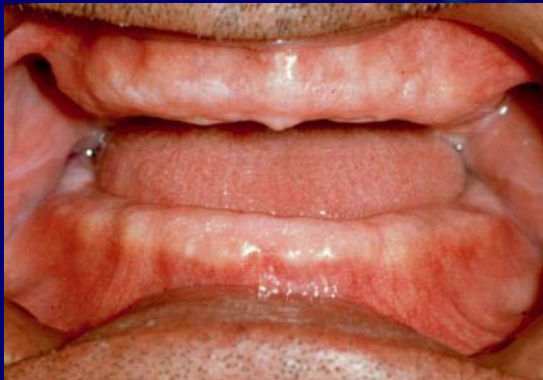Partial Dentate

Edentulous jaw

Etiology?

Socio-cultural
association

Disuse atrophy



Considerations relative to the condition

Wear

Single space

Partial Dentate

Edentulous jaw

Terminal dentition

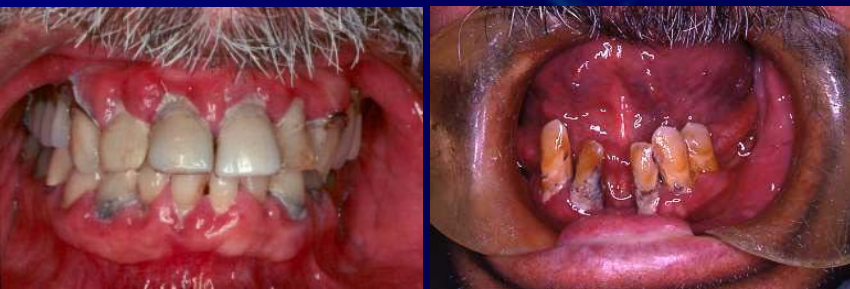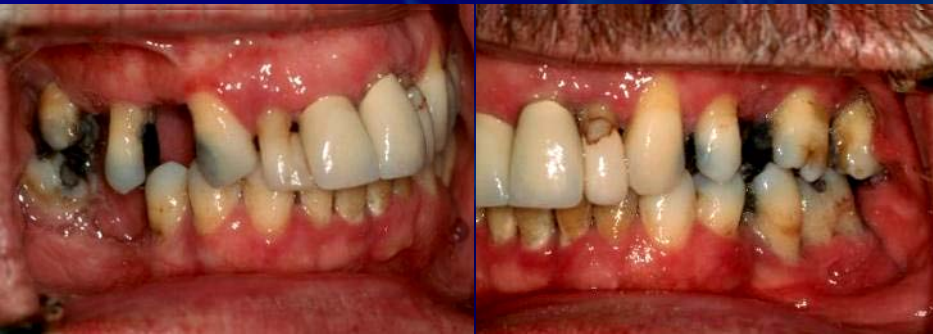Etiology?

Socio-cultural
association

Caries/Periodontitis

Oral Health

Negligence



Considerations relative to the condition

Wear

Single space

Partial Dentate

Edentulous jaw

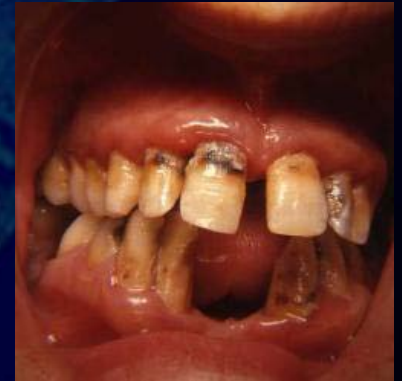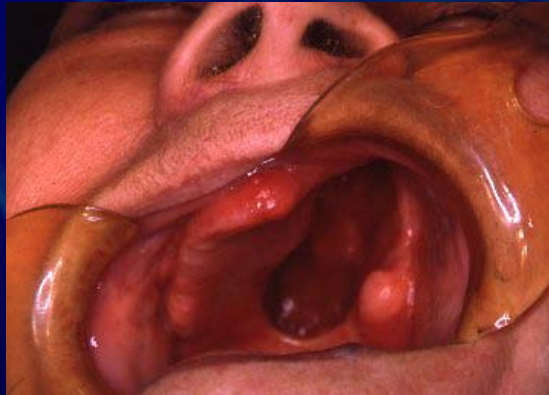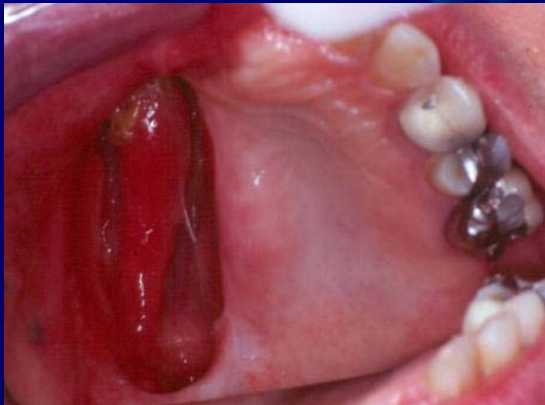Terminal dentition

Extensive tissue loss

Etiology?:

Trauma

Cancer



Considerations relative to the condition

Wear

Single space

Partial Dentate

Edentulous jaw

Terminal dentition

Extensive tissue loss

Congenital

Oligodontia

Cleft Lip/Palate

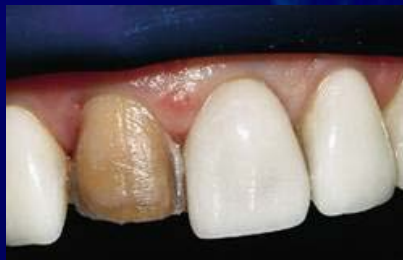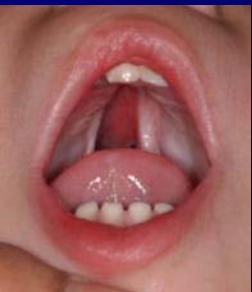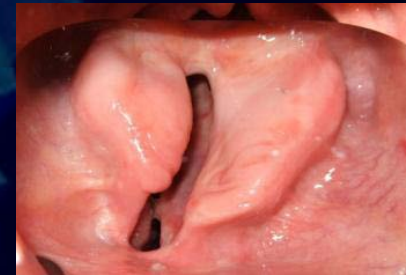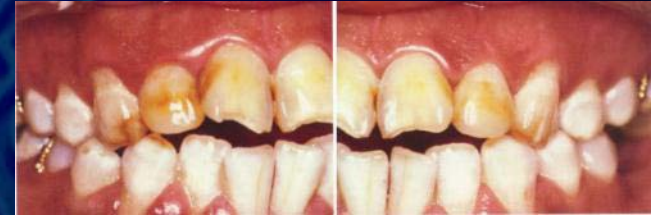Amelogenesis Imp.

Dentinogenesis Imp.

Osteogenesis Imp.

Ectodermal dysplasia

+++

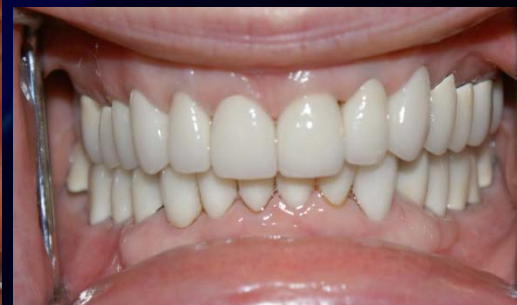
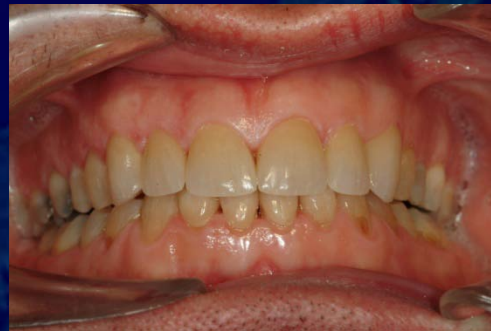
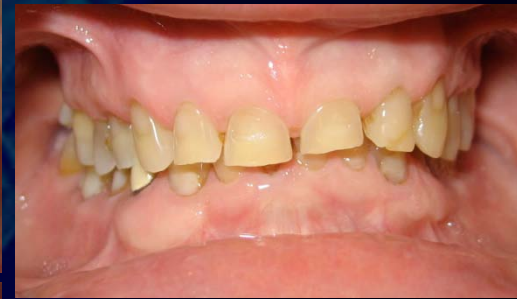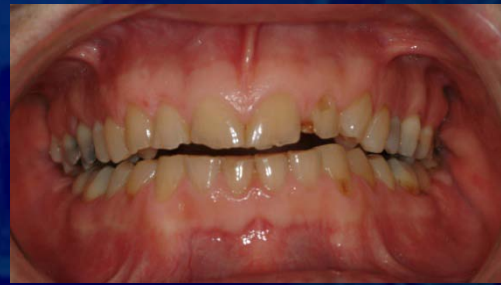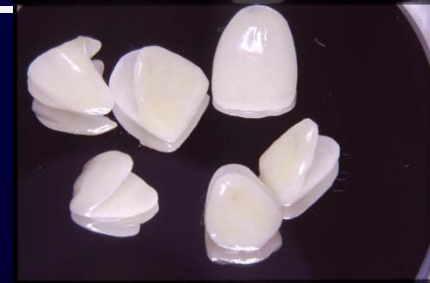PROCESS: Most common prosthetic solutions

Wear



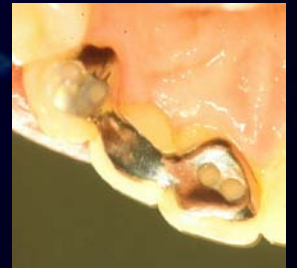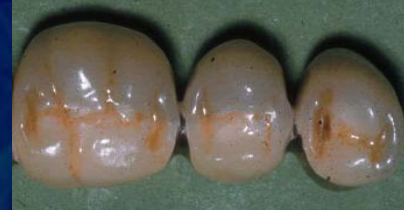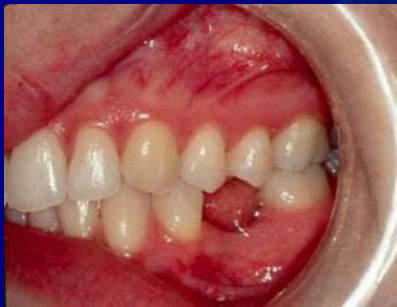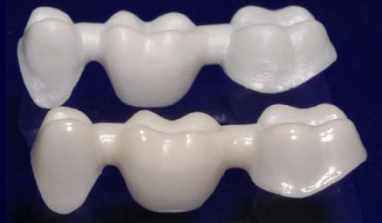Tissue-retained
Tooth / teeth-



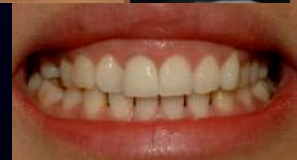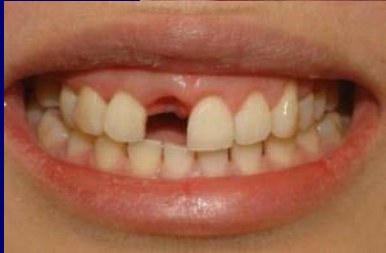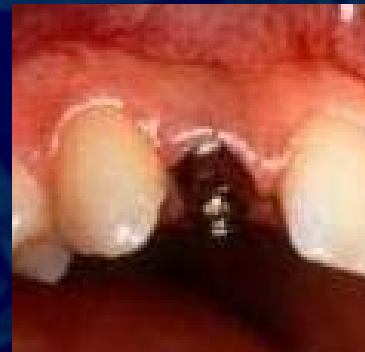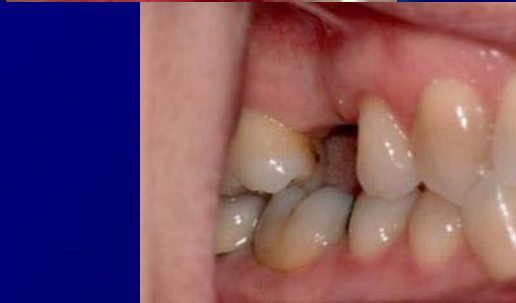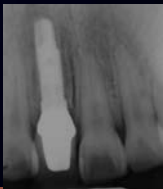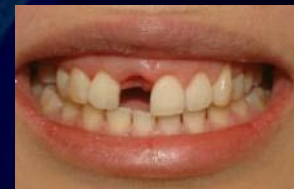PROCESS: Most common prosthetic solutions

Wear
Single

Tissue-retained
Tooth / teeth-



Implant-retained

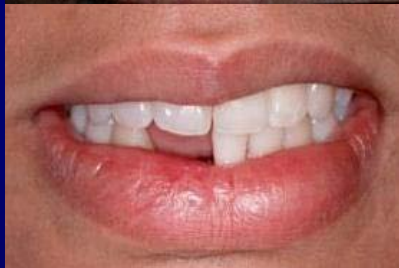
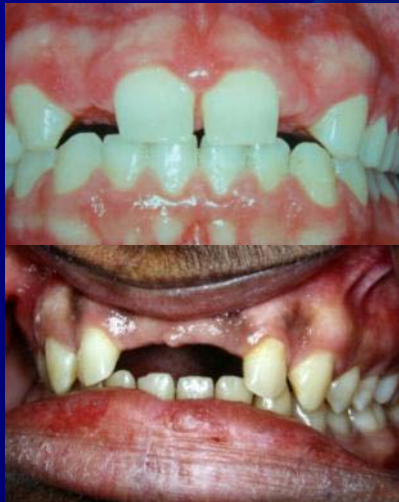
Inlay-bridge
Gold Veneer

PROCESS: Most common prosthetic solutions

*Wear
Single space*

Partial Dentate



Tissue-retained

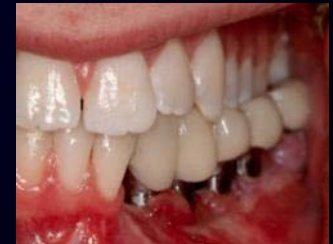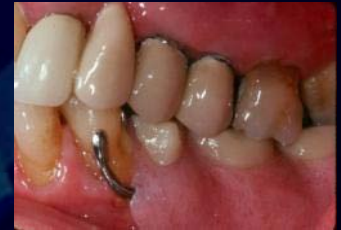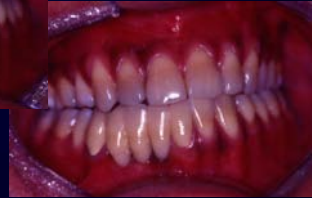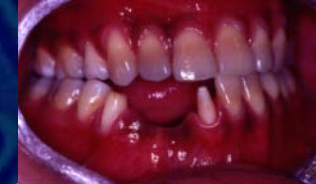Tooth / teeth-

Mucosa-

Tooth/teeth + mucosa-

Implant-retained

(Implant+tooth-)



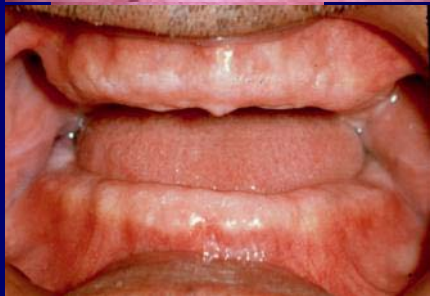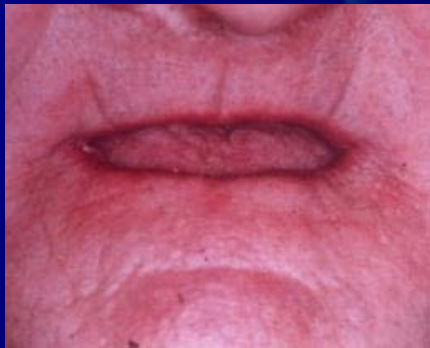PROCESS: Most common prosthetic solutions

Wear

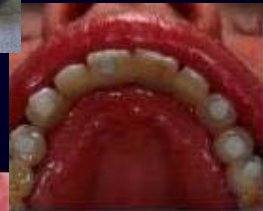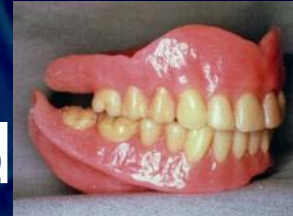Single space

Partial Dentate

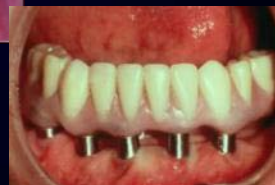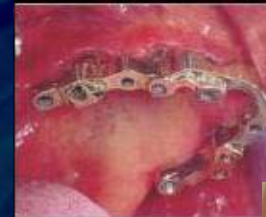Edentulous jaw



Tissue-retained

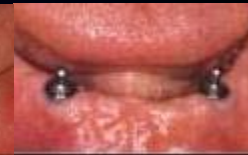
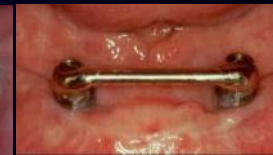
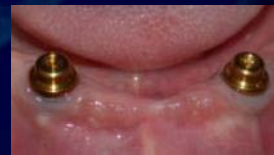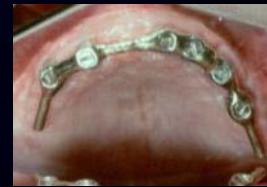Mucosa-



Implant-retained

Implant+mucosa-



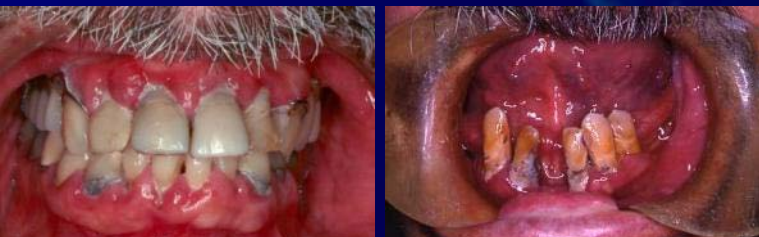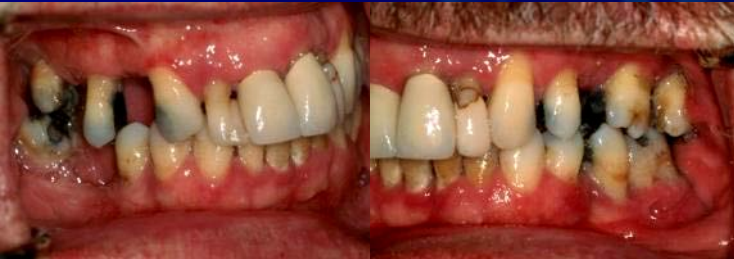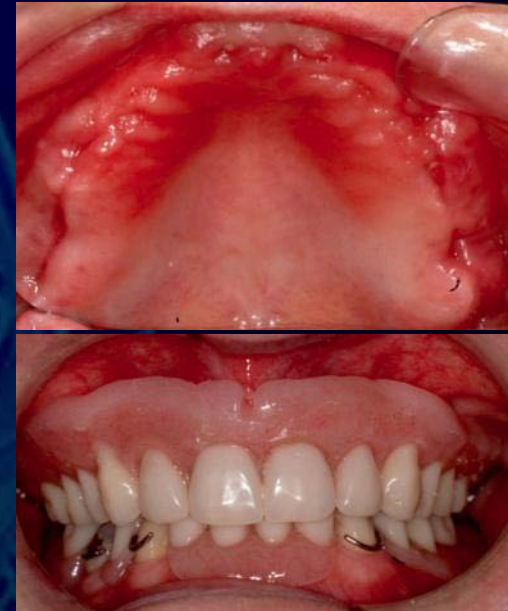PROCESS: Most common prosthetic solutions

Wear
Single space
Partial Dentate
Edentulous jaw
Terminal dentition

Tissue-retained

Mucosa-

(Implant-retained
Implant+mucosa)



PROCESS: Most common prosthetic solutions

Wear

Single space

Partial Dentate

Edentulous jaw

Terminal dentition

***Extensive
tissue loss***

Tissue-retained

Tooth / teeth-

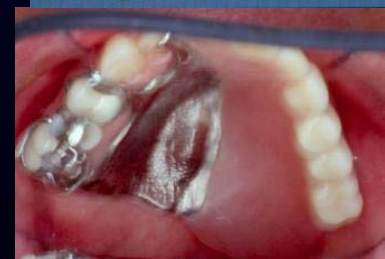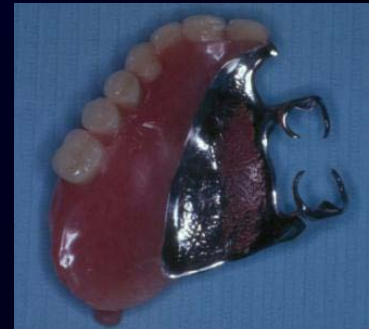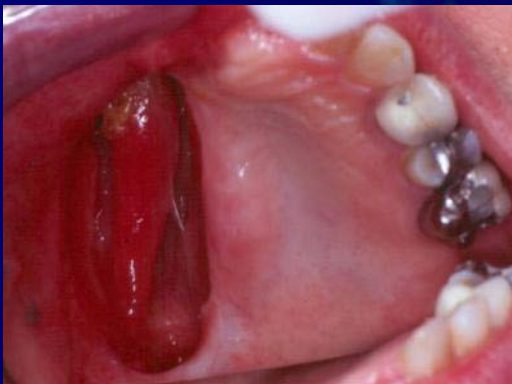Mucosa-

Tooth/teeth + mucosa-

Implant-retained

Implant+tissue-

(Implant+tooth-)



PROCESS: Most common prosthetic solutions

Wear

Single space

Partial Dentate

Edentulous jaw

Terminal dentition

Extensive tissue loss

Congenital

Tissue-retained

Tooth / teeth-

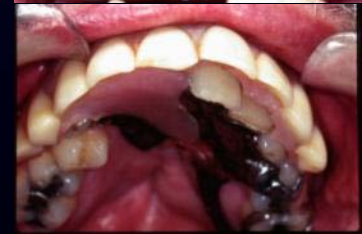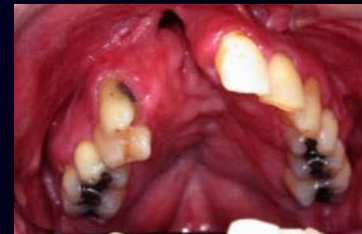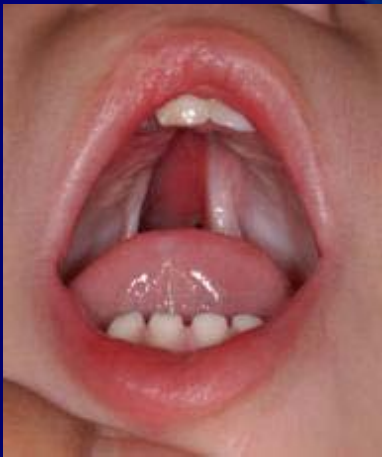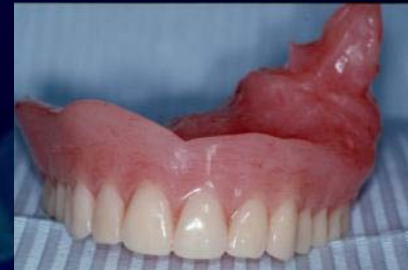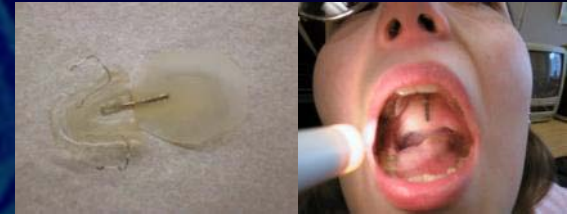Mucosa-

Tooth/teeth + mucosa-

Implant-retained

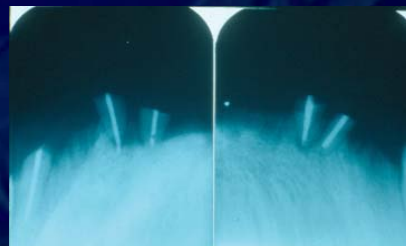
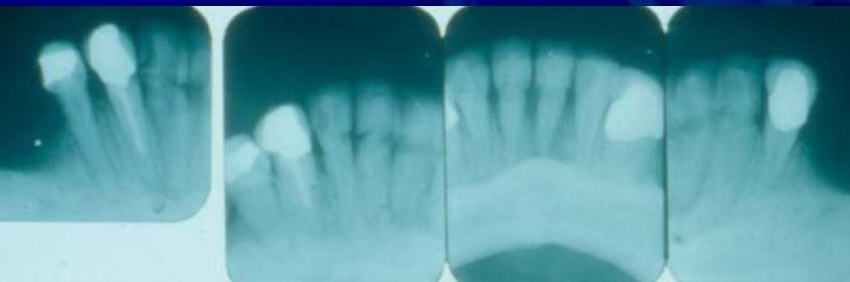Implant+tissue-

(Implant+tooth-)



A holistic approach to patient care

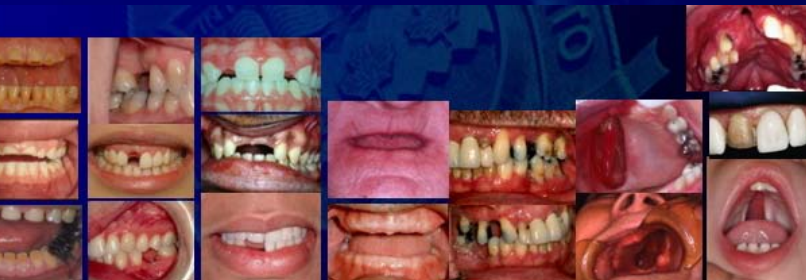Educating the patient how to avoid future oral disease (and treatment) is a component in all patient care.




A holistic approach to patient care

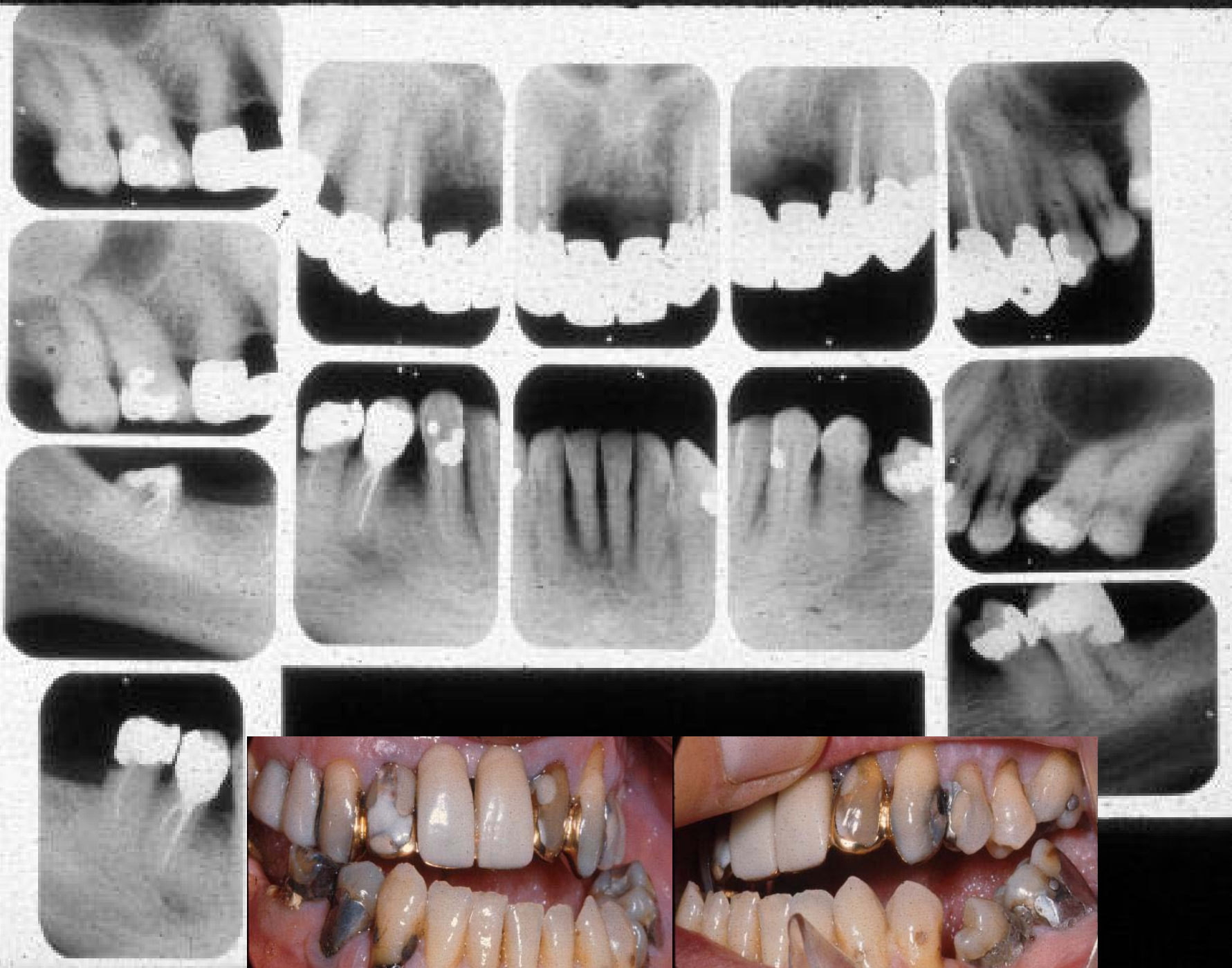Wear
Single space
Partial Dentate
Edentulous jaw
Terminal dentition
Extensive tissue loss
Congenital

1. **SITUATION:** What is the patient's problem?
2. **CAUSE:** What is at the root of the patient's problem?
Active Disease?
Consequences of a disease?
3. **PROCESS:** How can the patient's problem be solved?
4. **RESULT:** To what extent has the patient's problem been solved?
5. **PROGNOSIS:** How can the patient prevent future problems?

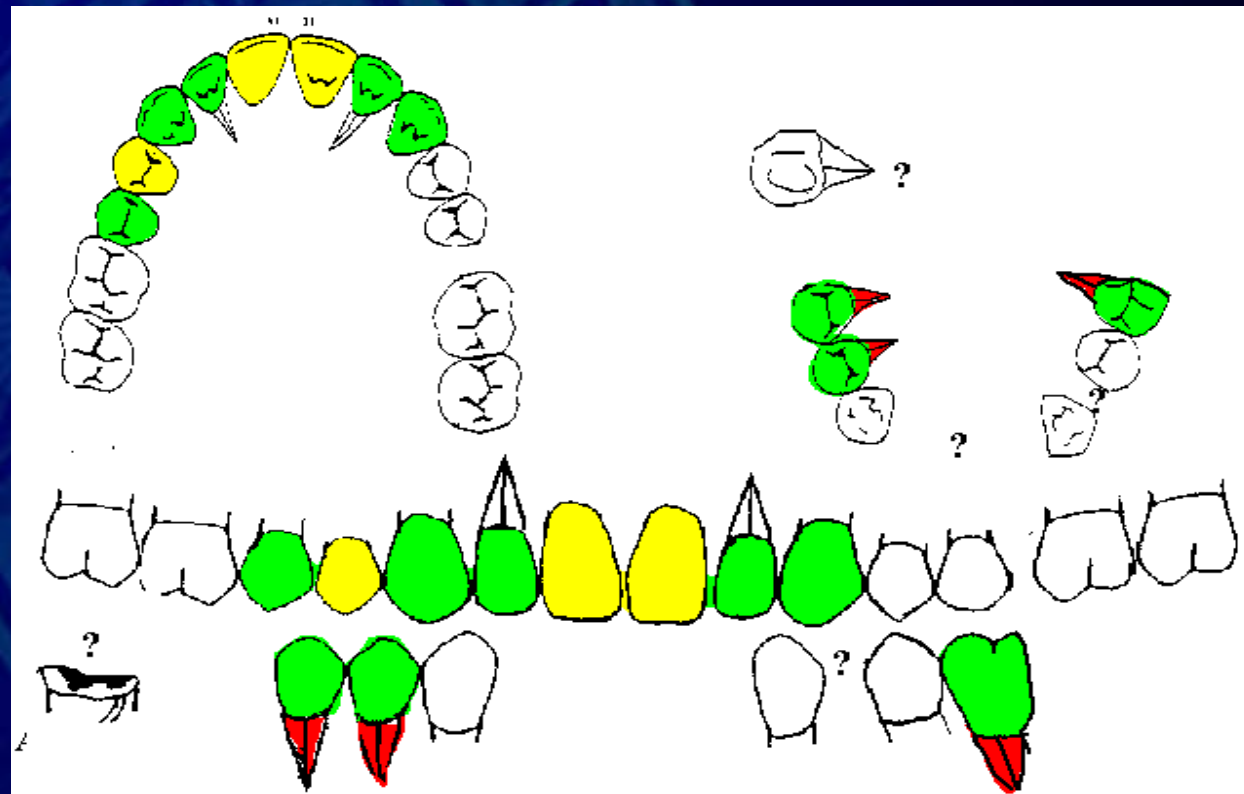
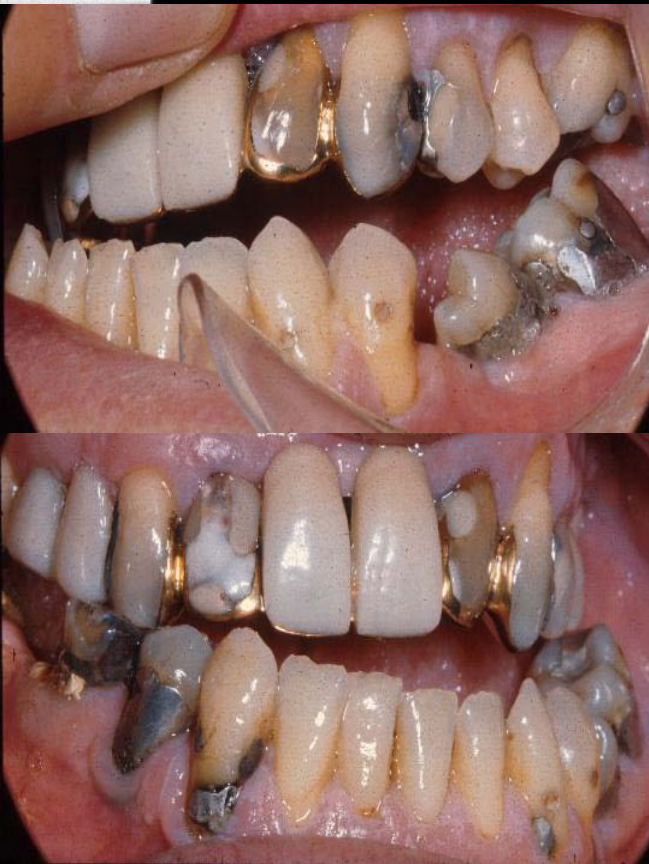
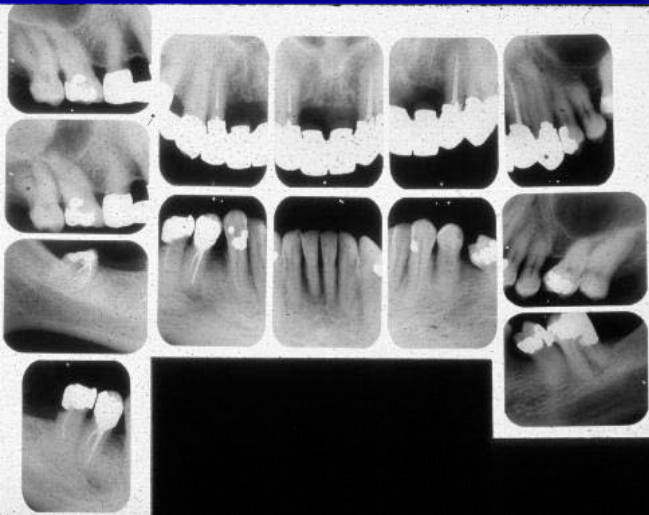
How to proceed for determining the optimal treatment for a patient with complex restorative needs?

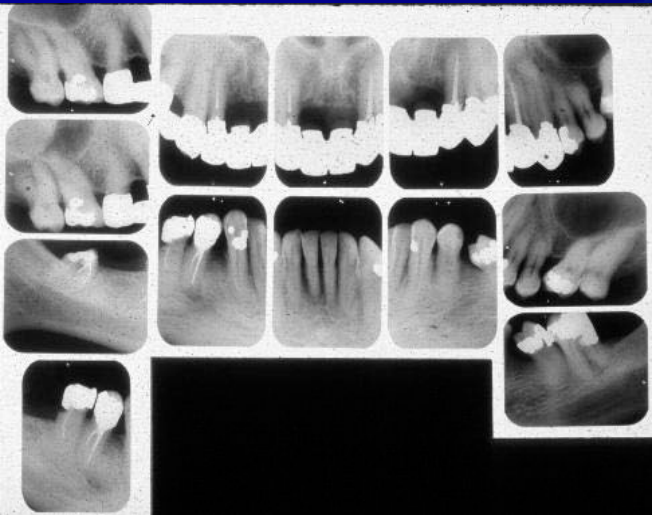



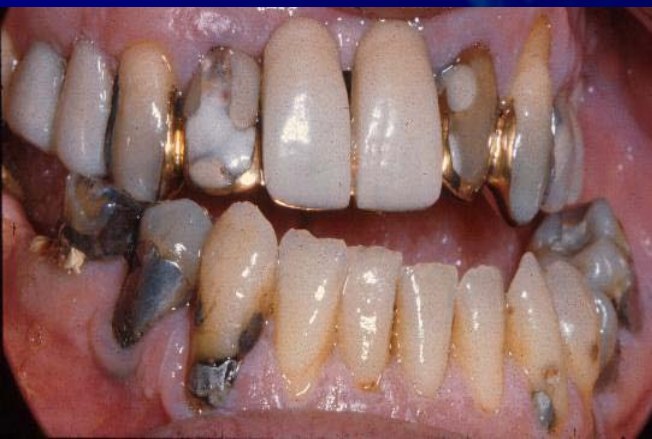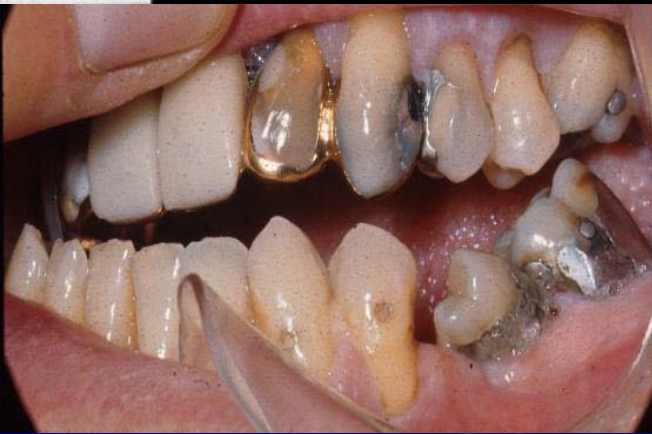1. Remove pathology:



Choice of restorative material? -retrograde endodontics?- extractions? - furcation surgery? - root separation? - orthodontics? -occlusal correction?

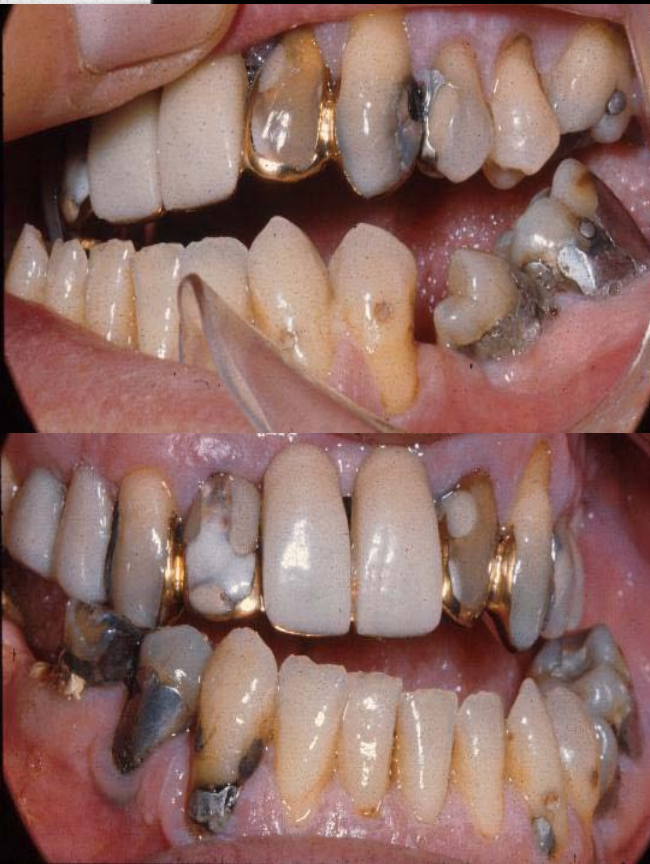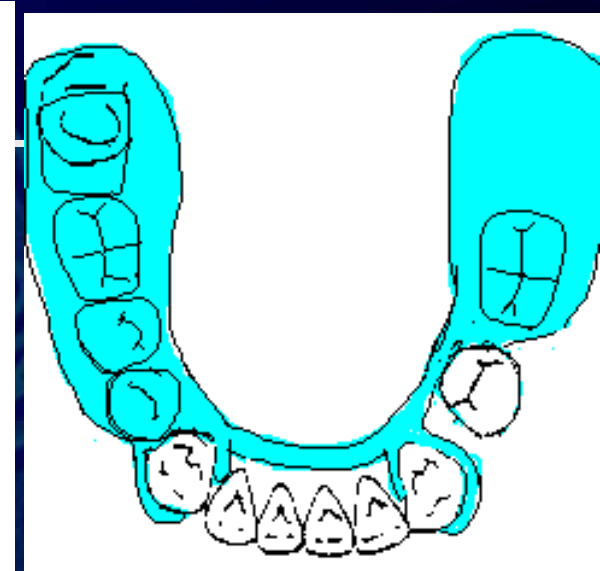
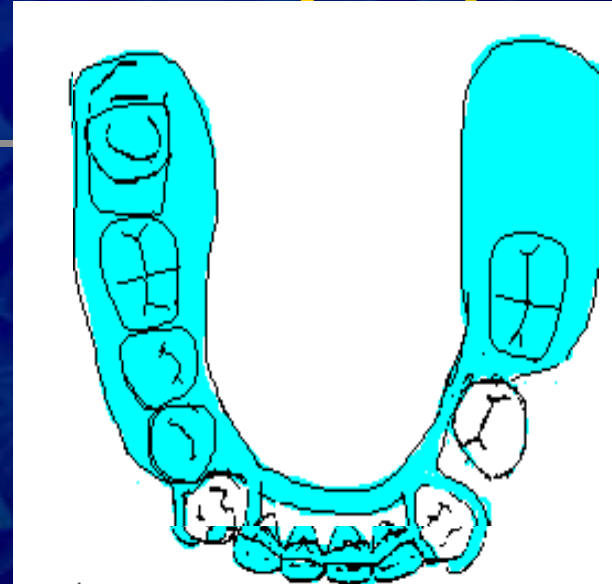

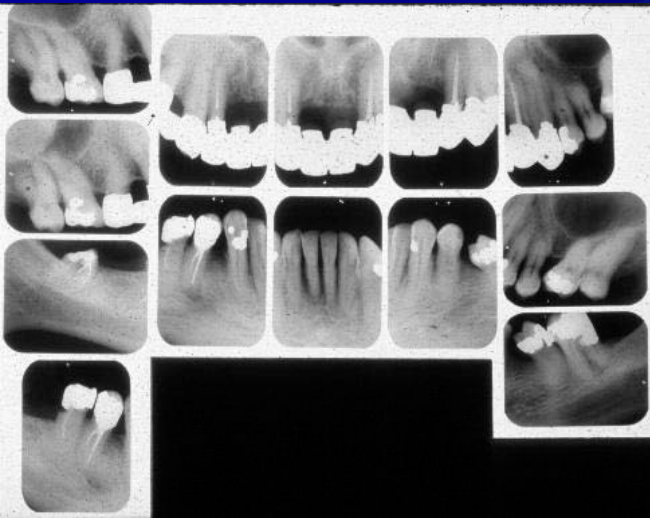
2. Choice of technical solution ?



- A. Restorative only, no prosthodontics
- B. Cast partial denture
- C. Crowns and partial denture
- D. Fixed bridge
- E. implant retained prosthesis

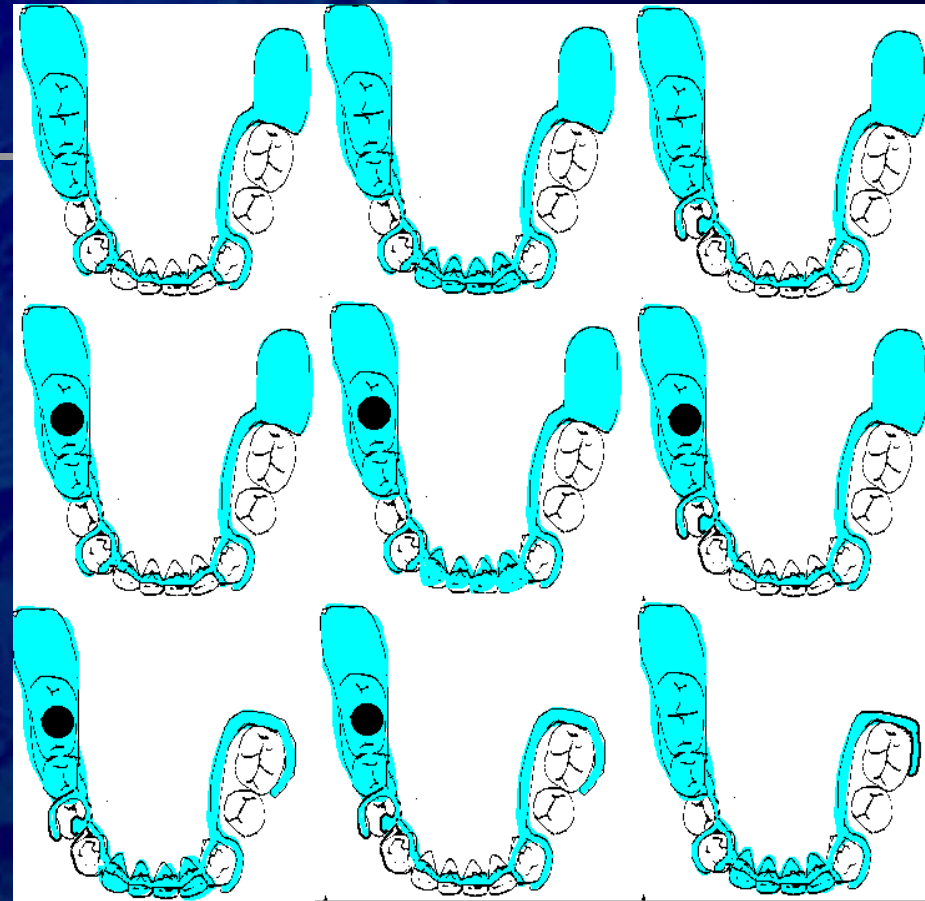
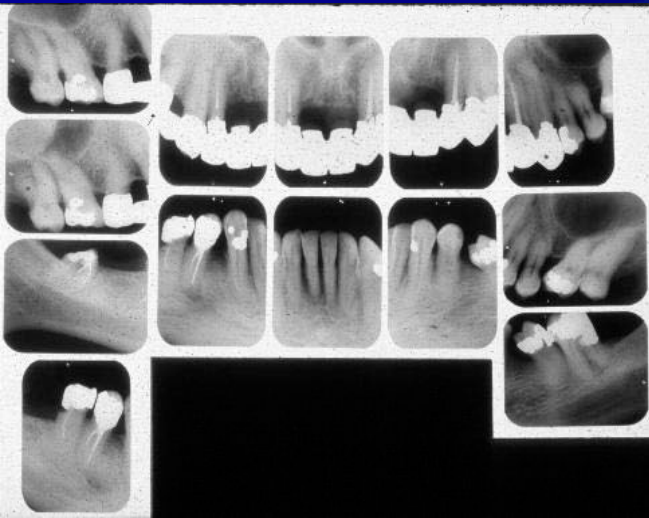Acrylic partial denture



Clinical knowledge

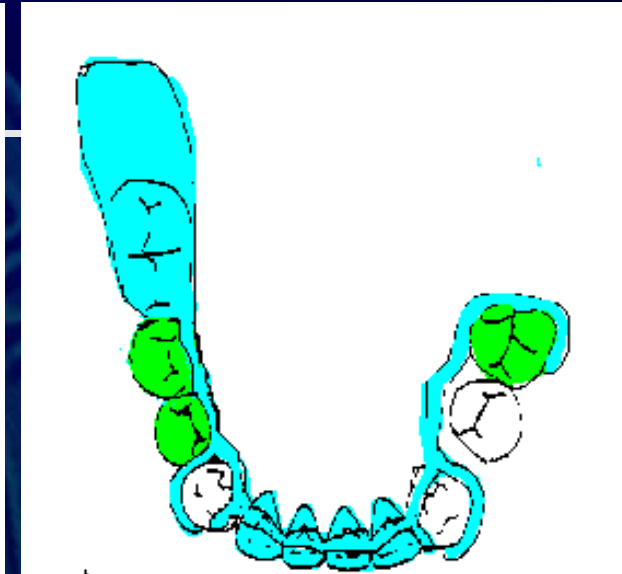
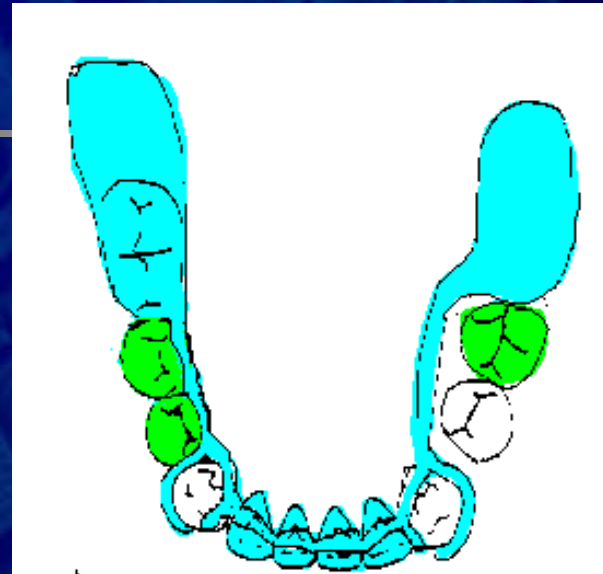
- n Prosthesis design
- n Prognosis

Cast partial denture



Clinical knowledge
Prosthesis design
Prognosis
Retention

Crowns + cast partial denture



Additional clinical knowledge

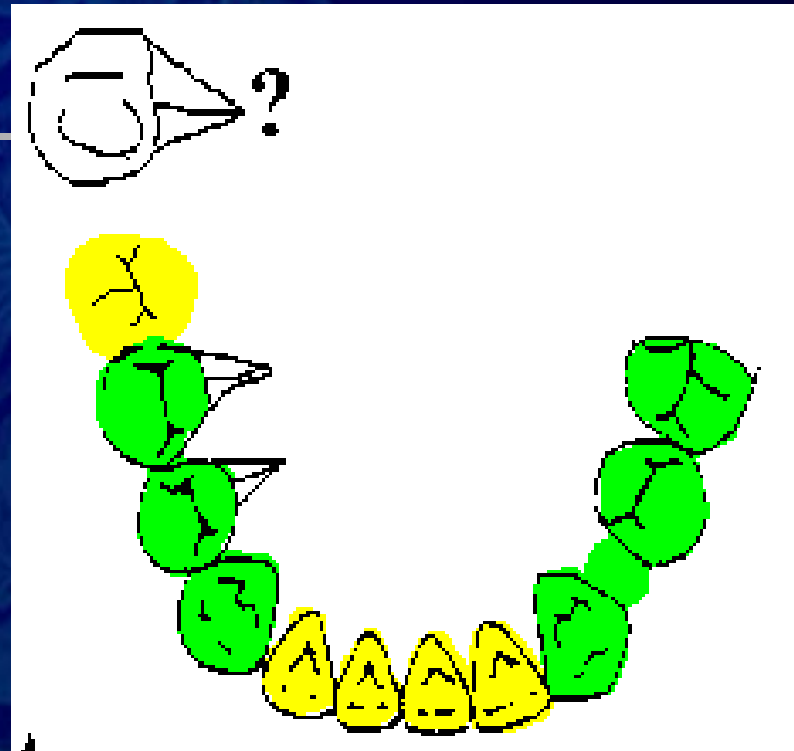
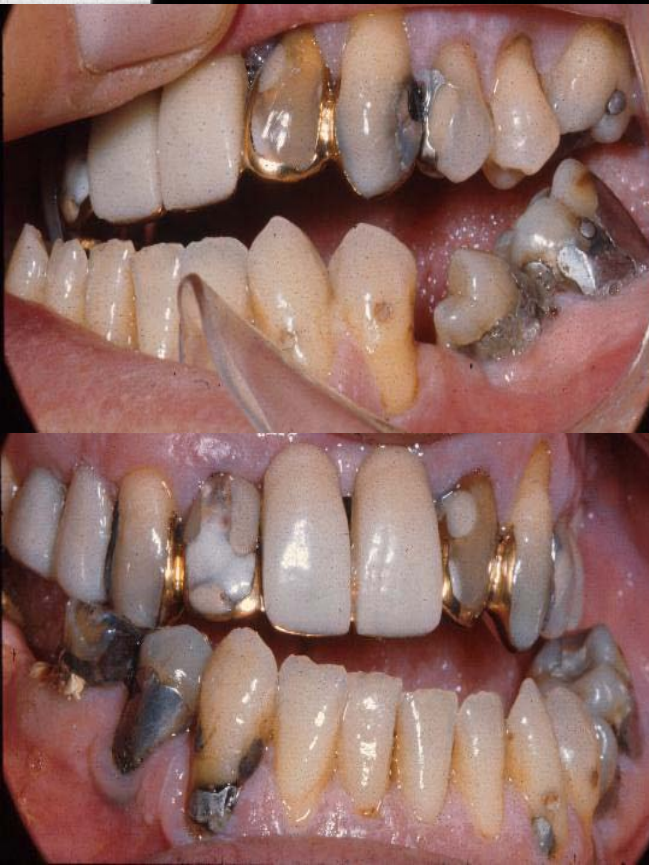36 extraction or crown?

Soldered 44 + 45?

Milled crowns?

Intra- or extracoronal attachments?

Fixed bridge



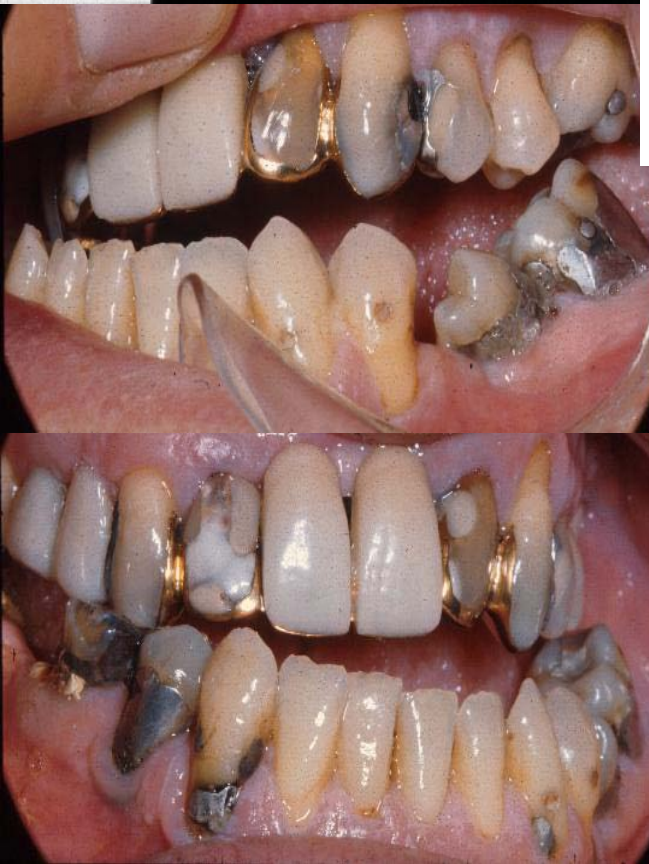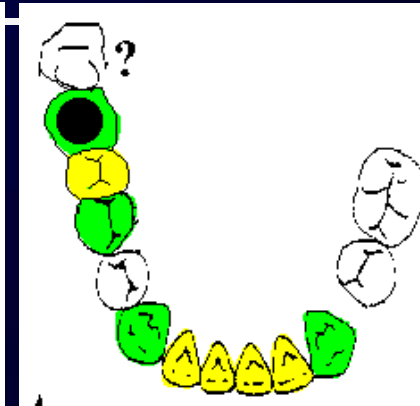
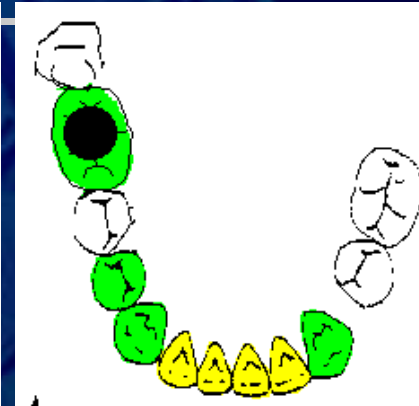
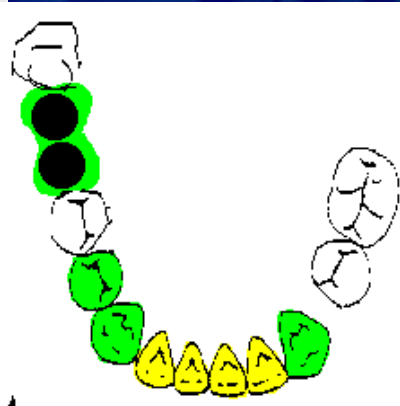
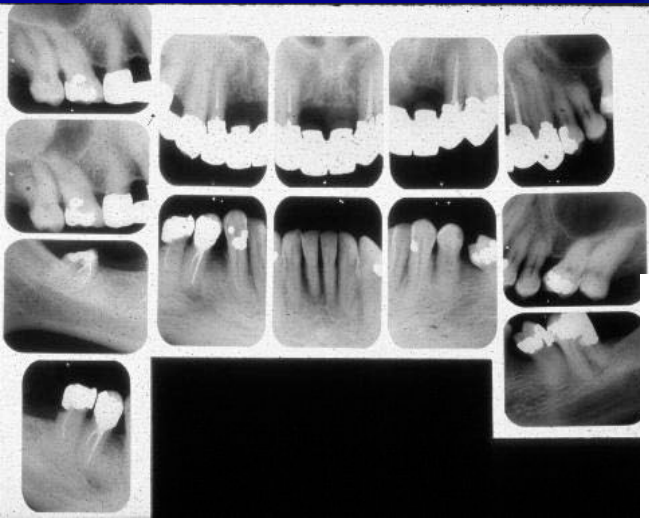Clinical knowledge

Conventional alloy, titanium-ceramic
or gold acrylic?

Zn-phosphate, GIC or resin cement?

Bridge extension 46? 46+47 ?

Implant retained prosthesis



Clinical knowledge

One / two implants?

Wide collar - standard diameter?

Splinted - non-splinted FPD?

Cement / screw-retained ?

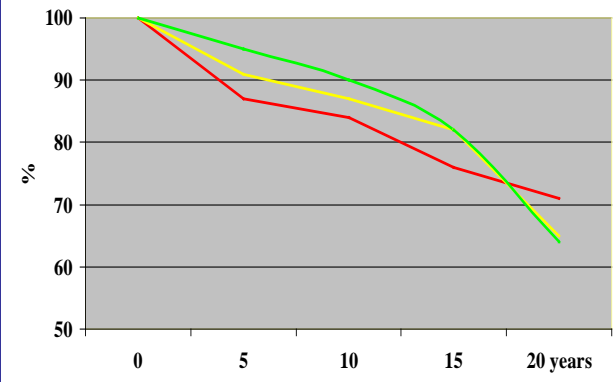
Nobelbiocare, AstraTech, 3i, Endopore,
Straumann, Friadent...?

Treatment planning

Overwhelming task
to appraise and
present information
for consent without
first communicating
with the patient!



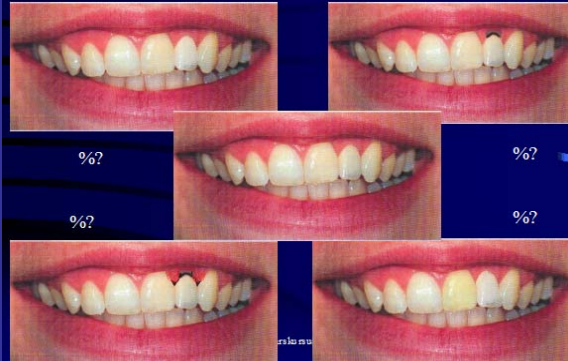Treatment decision considerations



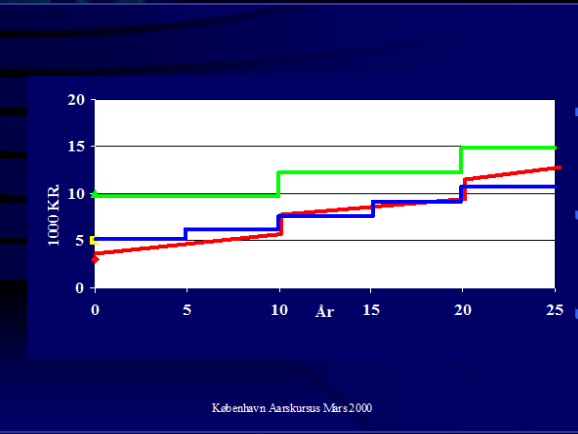
Independent variables	Bi-variate odds ratios	Bivariate significance	95% Confidence intervals bivariate odds ratios	Multi-variate odds ratios	Multivariate significance	95% Confidence intervals for multivariate odds ratios
Age group						
20-30	-	-	-	-	-	-
30-40	2.32	**	1.15 - 3.13	2.52	**	1.35 - 3.33
+40	2.63	***	1.43 - 3.08	2.63	***	1.83 - 3.8
Gender						
Male	-	-	-	-	-	-
Female	2.42	**	1.61 - 2.79	2.12	**	1.91 - 2.9
Material						
Amalgam	-	-	-	-	-	-
Composites	1.12	NS	0.13 - 1.56	1.42	NS	1.13 - 1.96
Glass ionom.	3.12	***	2.52 - 4.34	5.65	**	4.67 - 7.23
Dentists						
#1	-	-	-	-	-	-
#2	1.34	NS	0.35 - 1.61	1.04	NS	1.35 - 2.01
Location						
Mandible	-	-	-	-	-	-
Maxilla	1.55	*	1.17 - 2.04	1.15	*	1.57 - 2.14



Dentist:patient relationship
Two-way communication



- Longevity
- Risk factors
- Adverse events
- Accumulated costs
- Quality of Life




København Aarskursus Mars 2000



**Correct
Prosthodontic
Treatment
Planning**


=

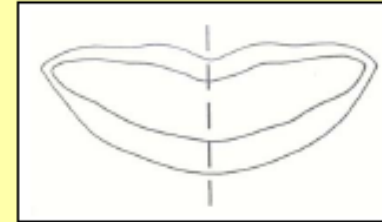
**Evidence-based
practice**



Examination with Prosthodontic Considerations :



• Lip support:  



• Smile line: 



• Profile (convex, concave, straight):


• Temporomandibular Function:

Reported symptoms:  


Clinical signs/symptoms:  

Range of movement (mm):

Normal	Open	R	L	Pain Muscle/TMJ?: Y/N
Slight impairment	Open	R	L	Pain Muscle/TMJ?: Y/N
Severe impairment	Open	R	L	Pain Muscle/TMJ?: Y/N

On guided closure, is there a slide to centric occlusion? If so, describe: 

• Freeway space: mm

• Is existing vertical dimension of occlusion adequate? (explain): 





• Should the plane of occlusion be modified? (explain): 



Chart #: _____
Date: _____

Examination with Prosthodontic Considerations :

- Lip support:
- Smile line:



- Profile (convex, concave, straight):

• Temporomandibular Function:

Reported symptoms:

Clinical signs/symptoms:

Range of movement (mm):

Normal	Open	R	L
Slight impairment	Open	R	L
Severe impairment	Open	R	L

On guided closure, is there a slide to centric occlusion? If so, describe:

• Freeway space: mm

• Is existing vertical dimension of occlusion adequate? (explain):

• Should the plane of occlusion be modified? (explain):

Version: July 2007

Reviewed by: _____
Signature: _____

- 14
- **Unaesthetic features:**
 - **Gingiva:**
 - Colour:
 - Contour / missing papilla:
 - Consistency:
 - **Edentulous ridge:**
 - Resorption:
 - Maxillary and mandibular ridge relation:
 - Clinical appearance/ consistency of mucosa:
 - Undercuts:
 - Morphology:

Summary of Findings for Potential Abutments:

- **Tooth number**

	Abutment 1	Abutment 2	Abutment 3	Abutment 4	Abutment 5
Mobility:					
Root form:					
Crown to root ratio:					
Caries:					
Extrusion:					
Rotation:					
Angulation:					
Periodontal status:					
Restoration quality:					
- **Endodontic status (from page 10)**
 - Pulp status:
 - Periradicular Disease:
 - PDL space contour:
 - "Quality" of current root filling:
- **Overall Prognosis of Abutment**

Reviewed by staff instructor:

(signature)

14

- **Unaesthetic features:**
- **Gingiva:**
 - Colour:
 - Contour / missing papilla:
 - Consistency:
- **Edentulous ridge:**
 - Resorption:
 - Maxillary and mandibular ridge relation:
 - Clinical appearance/ consistency of mucosa:
 - Undercuts:

Summary of Findings for Potential Abutments:

- **Tooth number** _____
- Mobility: _____
- Root form: _____
- Crown to root ratio: _____
- Caries: _____
- Extrusion: _____
- Rotation: _____
- Angulation: _____
- Periodontal status: _____
- Restoration quality: _____
- **Endodontic status (from page 10)**
- Pulp status: _____
- Periradicular Disease: _____
- PDL space contour: _____
- "Quality" of current root filling: _____
- **Overall Prognosis of Abutment** _____

Reviewed by staff instructor: _____
 (signature)

Form: July 2007

If prostheses are present, patient's report of:

- Age of present denture:
- Number of previous prostheses:
- If removable prostheses, wearing habit:
- Satisfaction with previous prostheses:
- Comfort:
- Chewing efficiency:
- Soreness:
- Food trapping:
- Aesthetics:
- Cleaning access/ability:

Sticky Note 31/07/2010 11:18:03 PM
jokstada Options
Upper: Constantly / Only when not sleeping/ Only occasionally / Never
Lower: Constantly / Only when not sleeping/ Only occasionally / Never

Sticky Note 31/07/2010 11:18:03 PM
jokstada Options
Tooth borne
Root covered
Full Removal
Implant supp
Implant supp
None / Acceptable / Unsatisfactory
Make a note if treatment expectations are discussed
in years

Sticky Note 31/07/2010 11:18:03 PM
jokstada Options
Last prosthesis: Satisfied / Unsatisfied
Second to last: Satisfied / Unsatisfied etc.
First prosthesis: Satisfied / Unsatisfied
Record reason(s) for past dissatisfaction

Sticky Note 31/07/2010 11:18:03 PM
jokstada Options
Good / Acceptable / Unsatisfactory

Sticky Note 31/07/2010 11:18:03 PM
jokstada Options
Good / Acceptable / Unsatisfactory
None / Acceptable / Unsatisfactory
Make a note if treatment expectations are discussed

Sticky Note 31/07/2010 11:18:03 PM
jokstada Options
Tooth form: Good / Acceptable / Unsatisfactory
Tooth shade: Good / Acceptable / Unsatisfactory
Prosthesis form: Good / Acceptable / Unsatisfactory
Make a note if treatment expectations are discussed

Sticky Note 31/07/2010 11:18:03 PM
jokstada Options
Good / Acceptable / Unsatisfactory

Sticky Note 31/07/2010 11:18:03 PM
jokstada Options
Why the question:
Identify cause and possibly rectify.

Sticky Note 31/07/2010 11:18:03 PM
jokstada Options
Why the question:
Consider not only the form and shade of the teeth. It may be that wrinkles /overcontoured flanges are perceived as problematic.

Sticky Note 31/07/2010 11:18:03 PM
jokstada Options
Why the question:
Rectify if the patient reports difficulties in being able to keep good oral hygiene.

Sticky Note 31/07/2010 11:18:03 PM
jokstada Options
Take into consideration manual dexterity that may compromise adequate oral hygiene
Poor oral hygiene will invariably cause problems and reduce the

Repl31/07/2010 11:18:03 PM
jokstada Options
Misprint - read: Prosthesis

Inser31/07/2010 11:18:03 PM
jokstada Options
any

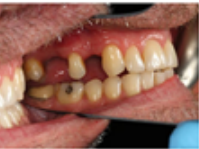Repl31/07/2010 11:18:03 PM
jokstada Options
Misprint - read: Ability

Course Sharepoint Website

Case 1

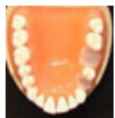Edentate, posterior maxilla

January 4th
January 6th



Supplement pictures

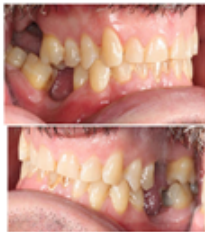Technical solutions used for patients with comparable teeth:



Case 2

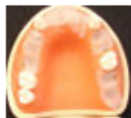Single missing teeth posterior in all 4 quadrants

Small group sessions -
Jan 4,6,7,11,13,20,25,27



Supplement pictures

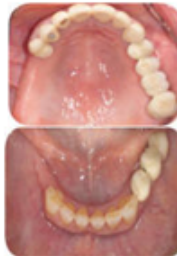Technical solutions used for patients with comparable teeth



Case 3

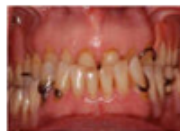Edentate posterior (Single quadrant free-end)
Maxilla (a)Mandible (b)

January 11th
January 13th



Supplement(a)
Supplement(b)
pictures

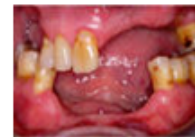Technical solutions used for patients with comparable teeth



Case 4

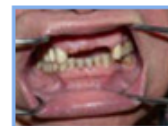Edentate anterior & posterior (bounded)

January 18th
January 20th



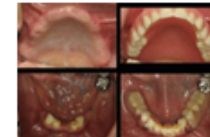Supplement pictures

Technical solutions used for patients with comparable teeth



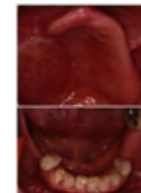Case 5 Complete Edentulous Maxilla + Edentate posterior (Free end) Mandible

January 25th
January 27th



Supplement pictures

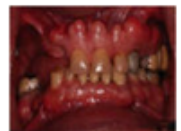Technical solutions used for patients with comparable teeth



Case 6

Complete Edentulous Maxilla & Mandible

February 1st
February 3rd



Supplement pictures

Technical solutions used for patients with comparable teeth